Poster Session P3 - Related Neurodegenerative Conditions - Synucleins and Lewy Body-Related Diseases
Tuesday, July 20, 2004

Abstract: P3-398

Citation: NeuroBiology of Aging, Volume 25, Number S2 , July 2004, Page 468

Using Deformation Morphometry to Investigate Tissue Loss in Dementia with Lewy Bodies

Colin Studholme[1,2], Kristine Yaffe[1,2], Valerie Cardenas[1,2], Norbert Schuff[1,2], Bruce Miller[1], Michael Weiner[1,2]

[1] University of California San Francisco, San Francisco, CA, USA; [2] VAMC, San Francisco, CA, USA. Contact e-mail: colin.studholme@ieee.org

Background: Dementia with Lewy Bodies is the second most common cause of dementia. Earlier studies of brain structure focused on region based tracing or gray matter only voxel based morphometry. A whole brain morphometry study of all tissue structures has so far not been carried out. **Objective(s):** To map differences in relative local anatomical size, measured using magnetic resonance imaging, in dementia with Lewy Bodies when compared to cognitively normal controls using whole brain deformation morphometry. **Methods:** High resolution (1x1x1.5mm) 3D T1 weighted coronal structural MRI (TR = 10ms, TE = 4ms) was acquired on 13 subjects diagnosed with DLB (9 Male, age = 73 (sd = 8)), together with 13 cognitively normal control subjects (9 Male, age = 73 (sd = 7)). 3D high resolution volume registration was used to estimate the transformation from a common reference MRI to each subject and the Jacobian of these transformations were analyzed at each voxel using a linear model to decompose the influence of dementia diagnosis, age and intra-cranial volume across the populations. **Results:** The most significant DLB related contraction effects ($P < 0.05$ corrected for multiple comparisons) were seen in the anterior white matter of the superior frontal gyri, descending into portions of the left anterior cingulate Contraction effects were also seen in a region of deep white and gray matter in the anterior portion of the left inferior parietal lobe, and in the right frontal pole. Less significant ($P < 0.005$ uncorrected) contraction effects were seen in the left and right orbital gyri, and localized to the gray matter strip of the left temporal lobe in the region of the lateral sulcus, the superior temporal sulcus and the fusiform gyrus, and in the right hippocampus and amygdala.

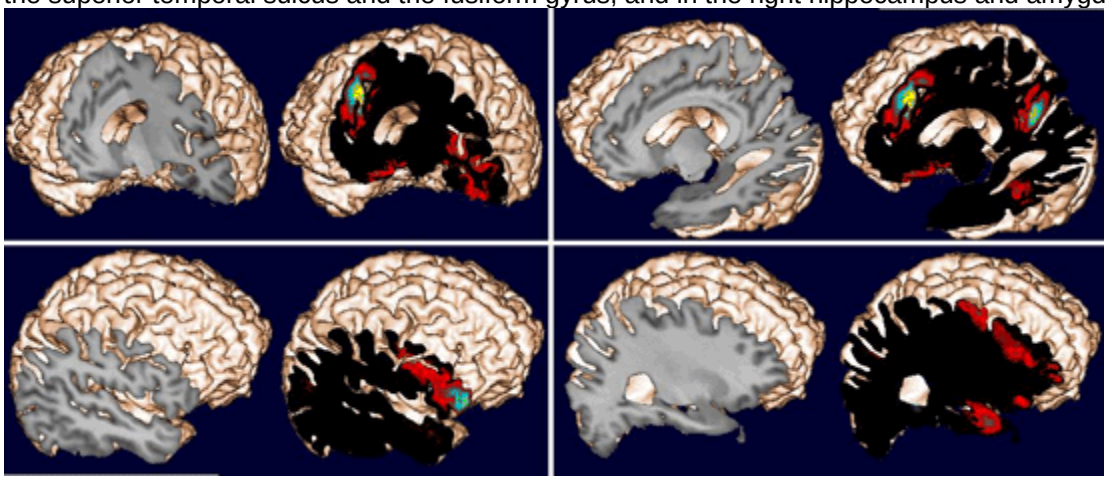

Fig. 1.

Conclusions: We observed focal gray matter losses in the left temporal lobe which were consistent with previously reported gray matter voxel morphometry findings. We found no structural differences compared to controls in the occipital lobe, which agrees with earlier ROI based structural imaging studies. We found however, that white matter losses in the anterior superior frontal gyri and deep parietal lobe, adjacent to the occipital lobe, provided the greatest statistical power to distinguish DLB from controls, perhaps reflecting the earliest structural effects of the disease.